

# Sudden Sensorineural Hearing Loss among Coronavirus Disease-19 Patients

Santosh Kumar Swain, Sweta Thakur

Department of Otorhinolaryngology, IMS and SUM Hospital, Siksha "O" Anusandhan University, Bhubaneswar, Odisha, India

## Abstract

Coronavirus disease-19 (COVID-19) is a new pandemic caused by severe acute respiratory syndrome coronavirus-2 (SARS-CoV-2) virus. COVID-19 patients often present with respiratory symptoms and death is the possible outcome. The potentiality for neuro-invasion by the SARS-CoV-2 is currently a subject of great debate. However, there is a paucity of information regarding impact of the SARS-CoV-2 on nervous system at the present moment. In fact, the impact of the coronavirus on the auditory system is little mentioned in the literature. Sudden sensorineural hearing loss (SSNHL) is rare symptom associated with COVID-19 infection. This hearing deterioration could be attributed to the damaging effects by viral infections on the outer hair cells of the cochlea but the exact mechanism is still unknown. Awareness about this nonspecific presentation like SSNHL in COVID-19 patients is often a challenge to a clinician for early management. Early identification of the SSNHL may be helpful for isolation of the patient and also protect their infectiousness in early period to prevent spread of the disease. Early identification of hearing impairment is also helpful for early medical treatment of SSNHL which can save the hearing. This article reviews the epidemiology, etiopathology, clinical presentations, investigations, and treatment of SSNHL in COVID-19 patients. This review article surely makes a baseline from where further prospective studies can be designed for this rare clinical entity in COVID-19 patients as not many studies are done.

**Keywords:** Cochlear function, COVID-19 infections, severe acute respiratory syndrome coronavirus-2, sudden sensorineural hearing loss

## INTRODUCTION

Hearing loss is a leading cause of disability worldwide. Hearing impairment has a vital role in communication and interaction, causing an invisible handicap of the affected person and psychological solitary confinement.<sup>[1]</sup> The link between the COVID-19 infection and hearing impairment is currently a challenge for health-care professionals.<sup>[2]</sup> COVID-19 infection is a highly contagious disease caused by the novel coronavirus called as severe acute respiratory syndrome coronavirus-2 (SARS-CoV-2) [Figure 1].<sup>[3]</sup> COVID-19 was first reported at Hubei, Wuhan province of China in December 2019.<sup>[3]</sup> This disease is found in the respiratory tract and usually transmitted by droplets from human to human. The common symptoms associated with COVID-19 infections include fever, cough, throat pain, headache, muscle pain, diarrhea, and dyspnea. There are some nonspecific neurological symptoms such as loss of smell and taste also found in some COVID-19 patients.<sup>[4]</sup> The association between the COVID-19 infection and sudden sensorineural

hearing loss (SSNHL) makes intuitive sense which is due to the neuropathic manifestations of the inner ear and auditory nerve. Although certain viral infections cause hearing loss, there is still unknown whether COVID-19 infection leads to auditory dysfunction or not. The hearing loss by viral infection may be due to direct damage to the inner ear structures like hair cells and organ of Corti or due to host immune-mediated damage. The hearing loss by viral etiology can be mild or severe to profound, unilateral or bilateral. In COVID-19 infections, the development of the SSNHL is rare and the exact etiopathology is difficult to explain in this current pandemic. The nonspecific

**Address for correspondence:** Dr. Santosh Kumar Swain, Department of Otorhinolaryngology, IMS and SUM Hospital, Siksha "O" Anusandhan University, K8, Kalinga Nagar, Bhubaneswar - 751 003, Odisha, India.  
E-mail: santoshvoltaire@yahoo.co.in

This is an open access journal, and articles are distributed under the terms of the Creative Commons Attribution-NonCommercial-ShareAlike 4.0 License, which allows others to remix, tweak, and build upon the work non-commercially, as long as appropriate credit is given and the new creations are licensed under the identical terms.

**For reprints contact:** WKHLRPMedknow\_reprints@medknow.com

**How to cite this article:** Swain SK, Thakur S. Sudden sensorineural hearing loss among coronavirus disease-19 patients. Matrix Sci Med 2021;5:63-7.

**Received:** 09-09-2020,

**Revised:** 01-10-2021,

**Accepted:** 07-10-2021,

**Published:** 14-11-2021


### Access this article online

Quick Response Code:



**Website:**  
www.matrixscimed.org

**DOI:**  
10.4103/mtsm.mtsm\_51\_20



**Figure 1:** Structure of the coronavirus disease-19 virus (blue arrow is spike protein over lipid membrane, red arrow indicates RNA)

symptom such as SSNHL could be the only presentations and helpful for identification of the COVID-19 patient. Hence, at present, SSNHL is a challenging and rare clinical entity among COVID-19 patients. This review article describes details of etiopathology, epidemiology, clinical presentations, diagnosis, and current treatment of the SSNHL among the COVID-19 patients.

## METHODS FOR LITERATURE SEARCH

We performed a literature review of SSNHL in COVID-19 patients during this current pandemic consisting database of PubMed, Medline, Scopus, and Google scholar search with terms COVID-19, SARS-CoV-2 virus, and SSNHL. We reviewed different current articles published in national and international journals. This manuscript reviews the details of SSNHL among COVID-19 patients including its epidemiology, etiopathology, clinical presentations, and treatment. This review article presents a baseline from where further prospective studies of SSNHL by SARS-CoV-2 could be designed and helps as a spur for further research in the COVID-19 pandemic and so prevent this morbid hearing handicap among COVID-19 patients even after their recovery from this disease and also helps to identify this infection early and prompt management.

## EPIDEMIOLOGY

The World Health Organization (WHO) has recorded that approximately 360 million people with disabling hearing impairment in the world which proved that more than half of the persons with hearing loss can be prevented by early diagnosis and treatment.<sup>[5]</sup> The link between COVID-19 infections and SSNHL is currently producing a challenge among the clinicians.<sup>[2]</sup> This gives an idea of neuropathic manifestations with involvement of the cochlea and auditory nerve. COVID-19 infection is rapidly spreading throughout the world and more than 200 countries across the globe

affected with this infection. The WHO declared the COVID-19 infection as global pandemic on March 11, 2020.<sup>[3]</sup> One study showed 20% cases of COVID-19 presented with SSNHL without any prior risk factors for hearing loss.<sup>[6]</sup> In this study, SSNHL was the only symptomatology found in COVID-19 patients with hearing loss, and none of them had other symptoms than SSNHL or any associated risk factors such as ototoxic drug intake, metabolic disease, history of trauma, and history of the infections at the upper respiratory tract. One interesting case report from Thailand, the second country which occurred after China, showed sensorineural hearing loss with COVID-19 infection. Approximately 1.22% cases of the COVID-19 infections were associated with SSNHL in Thailand.<sup>[7]</sup> Previously, other coronavirus infection had involved the brainstem and caused possible neuro-auditory system.<sup>[8]</sup> In this current pandemic, it is often challenging for a clinician to recognize the possible symptoms of COVID-19 patients including SSNHL and break the chain of transmission. There is not much study related to the SSNHL in COVID-19 patients. However, SSNHL also plays an important role for global public health in case COVID-19 patients with sole symptom of sudden sensorineural deafness.

## ETIOPATHOLOGY

SSNHL is often a known complication of viral infections. There is a plausible mechanism for virus-associated hearing loss. One report suggested an association between SARS-CoV-2 infection and encephalopathy with leptomeningeal enhancement in contrast imaging.<sup>[9]</sup> Hearing loss is a possible complication of viral or bacterial meningitis and found in approximately 7% of the cases.<sup>[10]</sup> There are three mechanisms for explaining the occurrence of SSNHL in viral infection. These are neuritis by viral infection affecting the cochlear nerve, involvement of the cochlea, and perilymphatic tissue, e.g., cochleitis by virus and stress response by cross-reaction of the inner ear antigens to the virus infections.<sup>[11]</sup> One animal study showed hearing loss occurred by direct infection of the inner ear or indirectly through cerebrospinal fluid.<sup>[12]</sup> There are some benefits of chloroquine and hydroxychloroquine for the treatment of COVID-19 infections, and the clinical trial for their efficacy is underway. These two drugs are typically used for the treatment of malaria and autoimmune diseases. There are reports in the literature for ototoxic effects which cause damage to the inner ear structures leading to the hearing loss, tinnitus, and vertigo. During evaluation of the COVID-19 patients with hearing loss, clinician should rule out the previous use of the chloroquine and hydroxychloroquine. The SARS-CoV-2 enters the human body at the airways and enters the cell by penetrating to the angiotensin-converting enzyme 2 (ACE2) at the lungs. Once the cytosolic pH reduces, the binding of the ACE2 to the virus will be easier.<sup>[13]</sup> The cytosolic pH decreases with increase of age, so the virus can lead to easy and heavy infections in the elderly persons.<sup>[13]</sup> The SARS-CoV-2 can attach to the hemoglobin and enter into the red blood cell/erythrocyte.<sup>[14]</sup> Then, this virus can

be moved with erythrocyte or vascular endothelium and affect all the tissues with ACE2. There are abundant ACE2 at the brain and medulla oblongata.<sup>[15]</sup> The auditory center of the brain is located at the temporal lobe where ACE2 is present. Overexpression of ACE2 in the brain except at the medulla oblongata has a positive effect like antioxidant and anti-inflammatory and regulator of the blood pressure.<sup>[15]</sup> However, if the cytosolic pH is less, raised ACE2 leads to increase viral load.<sup>[13]</sup> Hence, the SARS-CoV-2 infection may progress to more severity. The virus release excess cytokines at the auditory center of the brain and its surrounding area. Hence, it can cause permanent damage to the auditory center of the brain by raising oxidative damage. If there is excess activation of the virus at the auditory center of the brain, it can cause it hypoxic and lead to damage. The virus has also nature to cause increase of thrombosis risk. SARS-Cov-2 can infect the veins which drain the auditory center so can make a clot these vessels. This clot blocks the blood vessels and affects the hearing center, leading to the ischemic damage. Because of the impaired vascularity and susceptibility for thrombosis in elderly age people, hearing problems may happen by this above mechanism. The exact mechanism for this deleterious impact of the SARS-CoV-2 virus on the cochlear hair cells will require further research. There is a big gap in the understanding of the etiopathogenesis, epidemiology, clinical presentations such as hearing loss and human transmission of this disease. There should be a continuous monitoring of the hearing loss, and tracing of this COVID-19 is required to ensure the detail understanding of this inner ear pathogenesis.

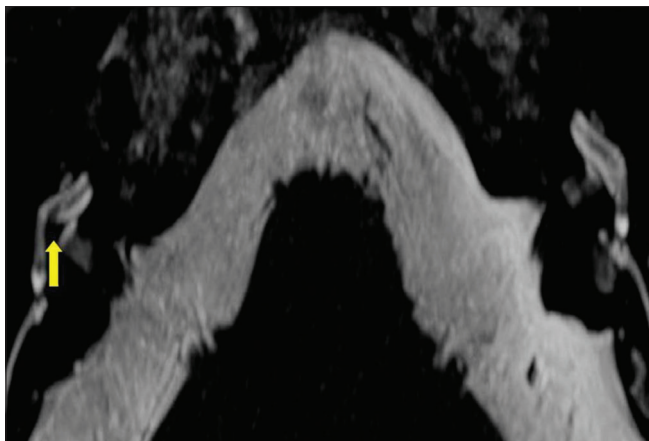
## CLINICAL PRESENTATIONS

The COVID-19 patients often present with respiratory symptoms. The common clinical symptoms are fever, cough, throat pain, myalgia, anosmia, taste disorders, and respiratory failure. In severe case, the COVID-19 infection can lead to pneumonia, respiratory failure, and death.<sup>[16]</sup> This viral infection can affect cranial nerves leading to SSNHL, peripheral facial nerve palsy, smell disturbances, and taste disorders.<sup>[17]</sup> The patients usually have no previous history of hearing impairment. The hearing loss by viruses can be mild or severe to profound, unilateral or bilateral. They often present with sudden onset of deafness in one ear. SSNHL is sensorineural hearing loss of sudden onset or one which happens in minutes, hours, or even in few days. It is usually unilateral (98%–99%).<sup>[18]</sup> Bilateral SSNHL is a rare incidence in clinical practice. SSNHL is defined as hearing loss more than 30 decibels at three consecutive frequencies at least over period of less than 3 days.<sup>[19]</sup> The deafness is sensorineural and profound hearing loss in one side. The other neurological manifestations were reported in literatures such as dizziness, ataxia, or stroke without taste or smell disorders and neuralgia because of the involvement of the peripheral cranial nerves.<sup>[16]</sup> This study emphasized the requirement of high alert and assessment of the neurological presentations in patients of SARS-CoV-2 infections for early diagnosis and prevention

of the spread of infection. There should be same approach for COVID-19 patients with SSNHL as sole symptom. Tinnitus often associated with SSNHL and other associated symptoms are dizziness, aural fullness, headache, nausea, and vomiting.<sup>[18]</sup> Many times the audiological symptom such as hearing loss may not be directly evaluated in COVID-19 patients as they may be in COVID hospital or quarantine center. Hence, the hearing status can be assessed by the telephonic conversation or video consultations.

## INVESTIGATIONS

Tuning fork test, pure tone audiometry, tympanometry, and otoacoustic emissions (OAE) are usually done to evaluate the SSNHL in patients with COVID-19 infection.<sup>[20]</sup> The type and degree of hearing loss are assessed by the tuning fork test and pure tone audiometry. The high-frequency sensorineural hearing loss is significantly associated with COVID-19 patients.<sup>[2]</sup> Typically viruses cause sensorineural hearing loss; however, viral etiology (measles) may be associated with otosclerosis which manifest conductive hearing loss.<sup>[21]</sup> HIV infection can also cause conductive hearing loss by bacterial or fungal infection following suppression of the immunity of body. Hearing loss in viral infection can be mild or severe to profound and unilateral to bilateral. Tympanometry is usually done to assess the middle ear pathology. Type-A tympanogram indicates normal middle ear whereas type-C indicates eustachian tube dysfunction. Majority of the COVID-19 patients with SSNHL show type-A tympanogram.<sup>[2]</sup> The airway infections in COVID-19 patients specifically infections or inflammations at the nasopharynx cause Eustachian dysfunction and responsible for type-C tympanogram. OAE represents a form of energy produced from the outer hair cells of the cochlea. OAE can be spontaneous (SOAEs), evoked by transient stimuli like clicks or tone bursts (TEOAEs). TEOAEs are not invasive and can be easily performed. For performing TEOAEs, the time is short, low cost, and high sensitivity.<sup>[22]</sup> In case of COVID-19 patients with SSNHL, TEOAEs show reduced amplitude which indicates subtle deterioration of the outer hair cell functions of the cochlea. The magnetic resonance imaging (MRI) with contrast of the brain and inner ear may show the inflammatory changes at the cochlea and auditory center.<sup>[23]</sup> Even cochlear ossification may be found because of the inflammation. MRI may show decreased fluid signal in the basal turn of the cochlea [Figure 2]. Thorough investigations should be done to find the exact etiology of the SSNHL and using treatment option in COVID-19 positive patients which can prevent such undesirable complications. Autopsy is thought to be the only way for giving definite evidence for auditory nerve involvement by the virus. In past MERS-CoV and SARS-CoV outbreaks, different studies showed the presence of the viral nucleic acid in cerebrospinal fluid and autopsy studies revealed the neurological involvement by the virus.<sup>[24,25]</sup> Similarly, one study of the autopsy showed edematous and hyperemic brain tissue with neural degeneration.<sup>[26]</sup>



**Figure 2:** Magnetic resonance imaging showing decreased fluid signal in the basal turn of the right cochlea (yellow arrow mark)

## TREATMENT

Majority of the people infected by the COVID-19 infection experience mild to moderate respiratory symptoms and recover without requiring any special treatment.<sup>[27]</sup> However, COVID-19 infection with SSNHL is a challenge for a clinician in the current COVID-19 pandemic. SSNHL is considered as one of the otologic emergency. Hearing loss due to viral infections can be limited or reversed by appropriate treatment in time. The hearing loss may become permanent or regress to normal or lead to partial recovery. SSNHL in case idiopathic condition may spontaneously come to normal in 45 to 60% cases.<sup>[28]</sup> Corticosteroids play a vital role for treating the SSNHL.<sup>[29]</sup> It is challenging for a clinician to identify the etiology as COVID-19 infections for SSNHL and start appropriate treatment to get maximum clinical recovery with minimal side effects and complications. Corticosteroid is an important first-line drug for the treatment of the SSNHL.<sup>[29]</sup> The diagnosed cases of SSNHL are usually treated with oral prednisolone 1 mg/kg/day in tapering dose for 3 weeks.<sup>[29]</sup> Vitamin B with folic acid complex and along with proton pump inhibitor is also taken by patients daily in addition to corticosteroids. However, the use of the corticosteroids in the SARS-CoV-2 infections as in other viral infections can lead to increased severity of the infection and cause delayed clearance of the viral infections.<sup>[30]</sup> A study showed complete recovery of SSNH in COVID-19 infections with treatment by corticosteroids.<sup>[6]</sup> Transtympanic injection of corticosteroids can be recommended rather than systemic one; however, the chance of contamination of the SARS-CoV-2 is more with invasive procedure. Intratympanic injection is a better option in non-COVID-19 period where drugs such as dexamethasone, methylprednisolone, and prednisolone can be used in different dosing protocol such as every day (up to 8 sessions), every other day, three times a week, twice a week to weekly injection for 4 to 4 sessions.<sup>[31]</sup> Hyperbaric oxygen therapy can be used to increase the oxygen supplementation for possibly ischemic cochlear structures in case of SSNHL. Hyperbaric oxygen therapy can be recommended for a patients with 3 months of

onset of SSNHL after proper counseling or explaining about limited evidence and cost or side effects of this techniques, There several other treatment have been used for treatment of SSNHL such as volume expanders, vasodilators, and vasoactive substances (e.g., carbogen therapy, calcium channel blockers, pentoxifylline, prostaglandin E1, naftidrofuryl), thrombolytic, antioxidants, magnesium, histamines, diuretics, intravenous diatrizoate, and herbal medications.<sup>[32]</sup> The recovery of hearing is poor in case of SSNHL in comparison to young patients.<sup>[20]</sup>

## CONCLUSION

Hearing loss in COVID-19 infection has not received much attention by the health-care professionals. COVID-19 infection could have deleterious effects on the inner ear specifically on the hair cells of the cochlea despite patients are asymptomatic. SSNHL is a nonspecific symptom in COVID-19 infection. However, it can be the sole symptom in COVID-19 infection which helps to recognize the positive case. Awareness of this nonspecific symptom may be targeted in the present pandemic for prevention of the infections by isolating the patient. Early identification of SSNHL in COVID-19 patients can save the hearing and also patient. The proper understanding of the mechanisms behind hearing loss in COVID-19 infections needs further research.

## Financial support and sponsorship

Nil.

## Conflicts of interest

There are no conflicts of interest.

## REFERENCES

- Swain SK, Sahu MC, Baisakh MR. Early detection of hearing loss with connexin 26 gene assessment. *Apollo Med* 2017;14:150.
- Mustafa MW. Audiological profile of asymptomatic Covid-19 PCR-positive cases. *Am J Otolaryngol* 2020;41:1-3.
- Zhu N, Zhang D, Wang W, Li X, Yang B, Song J, *et al.* A novel coronavirus from patients with pneumonia in China, 2019. *N Engl J Med* 2020;382:727-33.
- Vaira LA, Salzano G, Deiana G, De Riu G. Anosmia and ageusia: Common findings in COVID-19 patients. *Laryngoscope* 2020;130:1787.
- World Health Organisation Fact Sheet. Deafness and hearing loss. In: *World Health Fact Sheet*. Geneva: World Health Organization; 2017. Available from: [www.who.int/mediacentre/factsheets/fs300/en](http://www.who.int/mediacentre/factsheets/fs300/en). [Last accessed on 2013 Mar 03].
- Kilic O, Kalcioğlu MT, Cag Y, Tuysuz O, Pektas E, Caskurlu H, *et al.* Could SSNHL be the sole manifestation of COVID-19? An investigation into SARS-CoV-2 in the etiology of sudden sensorineural hearing loss. *Int J Infect Dis* 2020;97:208-11.
- Yasri S, Wiwanitkit V. Editorial: Wuhan coronavirus outbreak and imported case. *Adv Trop Med Pub Health Int* 2019;9:1-2.
- Wege H, Watanabe R, Ter Meulen V. Relapsing subacute demyelinating encephalomyelitis in rats during the course of coronavirus JHM infection. *J Neuroimmunol* 1984;6:325-36.
- Helms J, Kremer S, Merdji H, Clere-Jehl R, Schenck M, Kummerlen C, *et al.* Neurologic features in severe SARS-CoV-2 infection. *N Engl J Med* 2020;382:2268-70.
- Fortnum H, Davis A. Hearing impairment in children after bacterial meningitis: Incidence and resource implications. *Br J Audiol* 1993;27:43-52.
- Wilson WR. The relationship of the herpesvirus family to sudden hearing

- loss: A prospective clinical study and literature review. *Laryngoscope* 1986;96:870-7.
12. Cashman KA, Wilkinson ER, Zeng X, Cardile AP, Facemire PR, Bell TM, *et al.* Immune-mediated systemic vasculitis as the proposed cause of sudden-onset sensorineural hearing loss following Lassa virus exposure in cynomolgus macaques. *mBio* 2018;9:e01896-18.
  13. Cure E, Cumhur Cure M. Comment on Organ-protective effect of angiotensin-converting enzyme 2 and its effect on the prognosis of COVID-19. *J Med Virol* 2020;92:1423-4.
  14. Liu W, Li H. COVID-19: Attacks the I-beta chain of hemoglobin and captures the porphyrin to inhibit human heme metabolism. *ChemRxiv* 2020;10:1-23.
  15. Krasniqi S, Daci A. Role of the angiotensin pathway and its target therapy in epilepsy management. *Int J Mol Sci* 2019;20:E726.
  16. Swain SK, Das S, Padhy RN. Performing tracheostomy in intensive care unit - A challenge during COVID-19 pandemic. *Siriraj Med J* 2020;72:436-42.
  17. Mateer EJ, Huang C, Shehu NY, Paessler S. Lassa fever-induced sensorineural hearing loss: A neglected public health and social burden. *PLoS Negl Trop Dis* 2018;12:e0006187.
  18. Vasama JP, Linthicum FH Jr. Idiopathic sudden sensorineural hearing loss: Temporal bone histopathologic study. *Ann Otol Rhinol Laryngol* 2000;109:527-32.
  19. Weiss D, Böcker AJ, Koopmann M, Savvas E, Borowski M, Rudack C. Predictors of hearing recovery in patients with severe sudden sensorineural hearing loss. *J Otolaryngol Head Neck Surg* 2017;46:27.
  20. Swain SK, Sahu MC, Choudhury J. Sudden sensorineural hearing loss in children: Our experiences in tertiary care teaching hospital of eastern India. *Pediatrics Polska-Polish Journal of Paediatrics* 2018;93:127-31.
  21. Karosi T, Kónya J, Petkó M, Sziklai I. Histologic otosclerosis is associated with the presence of measles virus in the stapes footplate. *Otol Neurotol* 2005;26:1128-33.
  22. Paludetti G, Ottaviani F, Fetoni AR, Zuppa AA, Tortorolo G. Transient evoked otoacoustic emissions (TEOAEs) in new-borns: Normative data. *Int J Pediatr Otorhinolaryngol* 1999;47:235-41.
  23. Degen C, Lenarz T, Willenborg K. Acute profound sensorineural hearing loss after COVID-19 pneumonia. *Mayo Clin Proc* 2020;95:1801-3.
  24. Desforges M, Favreau DJ, Brison E, Desjardins J, Meessen-Pinard M, Jacomy H, *et al.* Human Coronavirus: Respiratory Pathogens Revisited as Infectious Neuro-Invasive, Neurotropic, and Neurovirulent Agents. Boca Raton, Florida, United States: CRC Press; 2013. p. 93-122.
  25. Arabi YM, Balkhy HH, Hayden FG, Bouchama A, Luke T, Baillie JK, *et al.* Middle east respiratory syndrome. *N Engl J Med* 2017;376:584-94.
  26. Mao L, Jin H, Wang M, Hu Y, Chen S, He Q, *et al.* Neurologic manifestations of hospitalized patients with coronavirus disease 2019 in Wuhan, China. *JAMA Neurol* 2020;77:683-90.
  27. Guo YR, Cao QD, Hong ZS, Tan YY, Chen SD, Jin HJ, *et al.* The origin, transmission and clinical therapies on coronavirus disease 2019 (COVID-19) outbreak – An update on the status. *Mil Med Res* 2020;7:11.
  28. Stokroos RJ, Albers FW, Schirm J. Therapy of idiopathic sudden sensorineural hearing loss: Antiviral treatment of experimental herpes simplex virus infection of the inner ear. *Ann Otol Rhinol Laryngol* 1999;108:423-8.
  29. Hara JH, Zhang JA, Gandhi KR, Flaherty A, Barber W, Leung MA, *et al.* Oral and intratympanic steroid therapy for idiopathic sudden sensorineural hearing loss. *Laryngoscope Investig Otolaryngol* 2018;3:73-7.
  30. World Health Organization. Clinical Management of Severe Acute Respiratory Infection (SARI) When COVID-19 Disease is Suspected: Interim Guidance 2020;1:2.13; WHO Reference Number: WHO/2019-nCoV/clinical/2020.4; 2020.
  31. El Sabbagh NG, Sewitch MJ, Bezdjian A, Daniel SJ. Intratympanic dexamethasone in sudden sensorineural hearing loss: A systematic review and meta-analysis: Intratympanic Dexamethasone for SSNHL. *Laryngoscope* 2017;127:1897-908.
  32. Singh A, Irugu DV. Sudden sensorineural hearing loss – A contemporary review of management Issues. *J Otol* 2020;15:67-73.