

Microscopic Surgical Anatomy of the Stapedius Muscle in Fresh Cadaveric Temporal Bone: Our Experiences

Santosh Kumar Swain, Somya Ranjan Pani

Department of Otorhinolaryngology and Head and Neck Surgery, IMS and SUM Hospital, Siksha "O" Anusandhan University, Bhubaneswar, Odisha, India

Abstract

Introduction: Stapedius muscle is the smallest bone in the human body and it has an important role for preventing loud noise exposing to the inner ear. This stapedius muscle has also a very significant role during stapes surgery for otosclerosis. **Materials and Methods:** We studied the microscopic anatomy of the 36-stapedius muscle at our temporal bone dissection laboratory during the period of March 2019 to April 2021. All the 36 fresh temporal bones were dissected with the help of the microdrill, burr, and Zeiss microscope. Details of the stapedius muscle anatomy such as origin, extension, and attachment were studied. **Results:** The length of the stapedius muscle was ranging from 8 to 11 mm. The tendon of the stapedius muscle was ranging from 1.5 to 2.5 mm. The classical shape of the stapedius muscle was sickle shape. The bulky bell of the stapedius muscle was from 1.5 to 3.5 mm. **Discussion and Conclusion:** Clear anatomical knowledge of the stapedius muscle is needed for the postgraduates and during learning period of the otologist. If anatomical knowledge is not clear, it may lead to confusion between the stapedius muscle and facial nerve. Awareness regarding microscopic anatomy is required for avoiding the confusion between the facial nerve and stapedius muscle or during the facial nerve grafting.

Keywords: Facial nerve, microscopic anatomy, stapedius muscle, stapes surgery

INTRODUCTION

Stapedius muscle is the smallest skeletal muscle in the human body. It has an important role in the stapes surgery and facial nerve decompression.^[1] Stapedius muscle is one of the intratympanic muscles helpful for preventing entrance of the loud noise into the inner ear. This muscle has a surgical importance in otology. The stapedius muscle is originated from the fasciculus of the posterior belly of the digastric muscle, which is attached in the mastoid groove and this fasciculus goes through stylomastoid foramen and attaches to the neck of the stapes to form stapedius muscle.^[2] The stapedius muscle is developed from the second branchial arch and gets innervations from the nerve fibers of the vertical or mastoid segment of the facial nerve, called as nerve to stapedius. The blood supply of the stapedius muscle is by stapedial branch of the posterior auricular artery. The stapedius muscle along with tensor tympani muscle contracts to dampen the amplitude of the loud sound and prevent from the excess movement of the stapes.^[3] Hence, stapedius muscle protects against the hazardous noise and enhances the speech perception, even in the presence of the background loud noise. If the stapedius muscle is paralyzed,

it causes hyperacusis where the person gets normal sounds as abnormally louder.^[4] The surgical anatomy of the stapedius muscle is very important for micro-ear surgery, especially in stapedotomy where the tendon of the stapedius muscle needs to be cut. Because of the surgical importance of the stapedius muscle in otologic surgery, we undertook this study toward microscopic evaluation of the stapedius muscle.

MATERIALS AND METHODS

This is an observational study done at our temporal bone dissection laboratory in a tertiary care teaching hospital done during March 2019 to April 2021. This study was approved

Address for correspondence: Dr. Santosh Kumar Swain,

Department of Otorhinolaryngology and Head and Neck Surgery, IMS and SUM Hospital, Siksha "O" Anusandhan University, K8, Kalinga Nagar, Bhubaneswar - 751 003, Odisha, India.
E-mail: santoshvoltaire@yahoo.co.in

This is an open access journal, and articles are distributed under the terms of the Creative Commons Attribution-NonCommercial-ShareAlike 4.0 License, which allows others to remix, tweak, and build upon the work non-commercially, as long as appropriate credit is given and the new creations are licensed under the identical terms.

For reprints contact: WKHLRPMedknow_reprints@wolterskluwer.com

How to cite this article: Swain SK, Pani SR. Microscopic surgical anatomy of the stapedius muscle in fresh cadaveric temporal bone: Our experiences. *Matrix Sci Med* 2022;6:14-7.

Received: 09-11-2021, **Revised:** 10-11-2021,

Accepted: 10-11-2021, **Published:** 25-01-2022

Access this article online

Quick Response Code:



Website:
www.matrixscimed.org

DOI:
10.4103/mtsm.mtsm_16_21

from our institutional ethical committee. We conducted 36 temporal bone dissections with demonstration of the middle ear ossicles and stapedius muscle and tendon. The dissected temporal bone was studied for the stapedius muscle with its origin to the insertion as per part of demonstration to our postgraduates. 36 fresh cadaveric temporal bones were dissected for the study of the surgical anatomy of the stapedius muscle. We used the S7 model Zeiss microscope, stapedotomy instruments, and the microdrill. The posterior tympanomeatal flap [Figure 1] was elevated transmeatally after making incision at 5 mm away from tympanic sulcus, which extends from 12 “O” clock to 6 “O” clock. We delineated the stapedius muscle including its origin, attachment, extension, and size. Bone curette was used to remove the bony overhanging above the stapedius muscle for clear exposure of this muscle. Excessive removal of the bony overhanging for visualization of the stapedius muscle may lead to subluxation of the incus. Hence, in this study, carefully bony curette was used for removal of the scutum done in few cases. A miniature thread/suture material was used to assess the length of the stapedius muscle. The pyramidal eminence and the stapedius muscle were excised in all the specimens for exposure of the retrotympanic area and evaluated for this region and assessment of exposure. The microscissor was used to cut the stapedius muscle for exposing the retrotympanic area and also footplate of the stapes. A cut piece of the suture material (Mersilk 5-0) was used to measure the length of the stapedius muscle.

RESULTS

In this study, 36 fresh cadaveric temporal bones were dissected as part of the postgraduate training during the 2-year study period. This temporal dissection was done in temporal bone laboratory at department of the Otorhinolaryngology. The trainees were exposed to surgical anatomy of the middle ear including ossicular chain and demonstrations of the stapedius muscle and tendon. All the 36 studied cadaveric temporal bone were fresh which were received from the forensic medicine

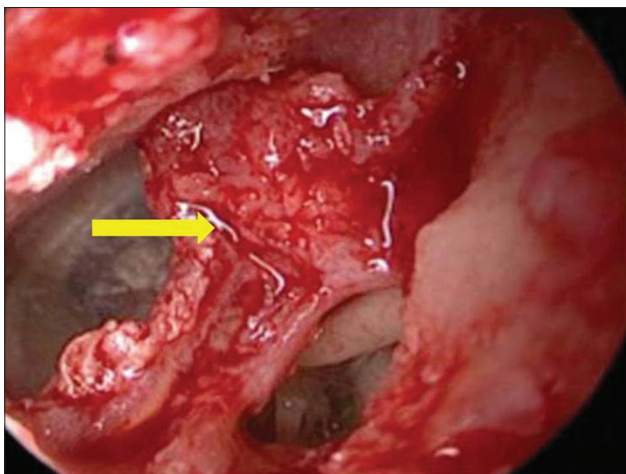


Figure 1: Elevation of the tympanomeatal flap (yellow arrow mark) before exposing the stapedius muscle

and anatomy department. After making tympanomeatal flap elevation, stapedius muscle was exposed. Out of the 36 cases, 9 cases (25%) required removal of the bony overhanging in the posterior tympanum to expose the complete stapedius muscle. Rest of the temporal bone did not require bony curettage or drilling of the scutum for exposure of the stapedius muscle. During exposure of the stapedius muscle, 3 cases (8.33%) showed overhanging of the tympanic segment of the facial bony canal [Figure 2]. The classical shape of the stapedius muscle was sickle shape whereas the stapedius tendon was appeared as handle of the sickle shape. The stapedius tendon was found in all the 36 temporal bones. The length of the stapedius muscle was ranging from the 8 to 11 mm with mean value was 10.60 mm. The length of the stapedius tendon measured from 1.5 to 2.5 mm with mean value being 2.10 mm. The stapedius muscle had bulky belly with breadth varies from 1.5 to 3.5 mm with mean value being 2.7 mm. The stapedius muscle [Figure 3] was located medial to the middle point of the vertical segment of the facial nerve. The stapedius muscle extends from the neck of the stapes at the posterior aspect and runs from superior to inferior direction. The tendon of the stapedius muscle was attached to the neck of the stapes and distal lower portion of the muscle was about 3.5 mm above the stylomastoid foramen. For exposing the lower one-third of the stapedius muscle(which is posteromedial to the mastoid/vertical segment of the facial nerve), the facial nerve is dissected and anterolaterally transpositioned. After cutting the stapedius muscle [Figure 4], there was exposure of the retrotympanic area and footplate of the stapes in all the cases [Figure 5].

DISCUSSION

Stapedius muscle is the smallest skeletal muscle of the human body.^[5] The first description of the stapedius muscle was done by the Paaw in the early part of the seventeenth century.^[6] At that period, there were awareness regarding presence of the

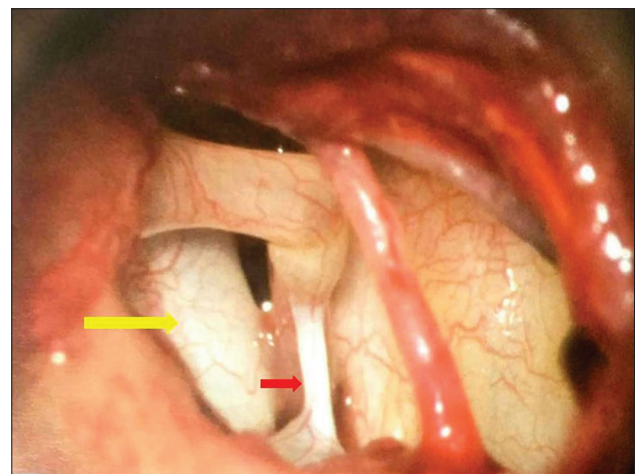


Figure 2: Overhanging of the tympanic segment of the facial nerve (yellow arrow mark) hiding the stapes and reaching towards the stapedius muscle (red arrow mark)

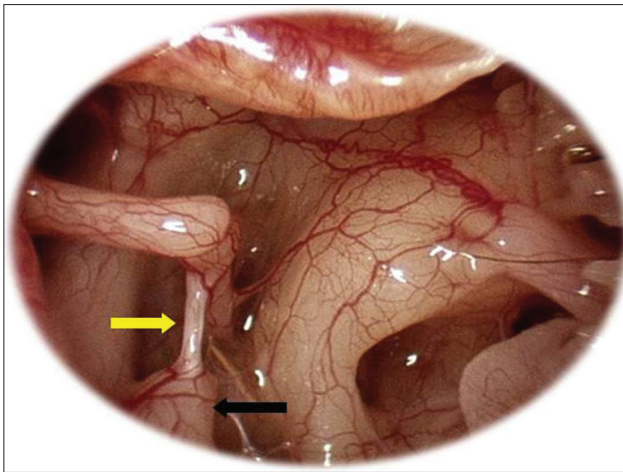


Figure 3: Complete exposure of the stapedius muscle (yellow arrow mark) and pyramidal eminence (black arrow mark)

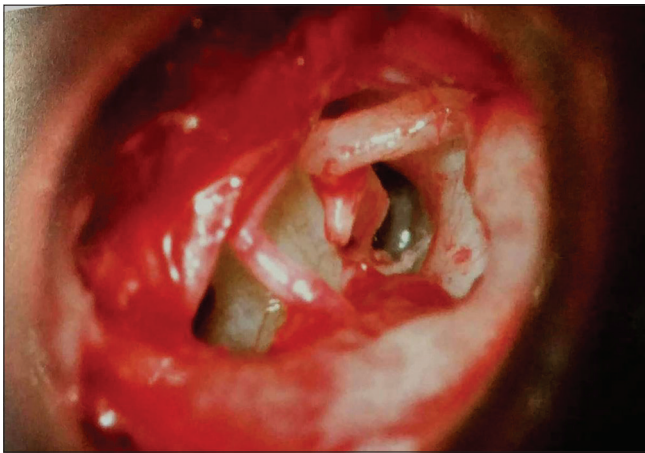


Figure 4: Cutting the stapedius muscle with micro-scissor

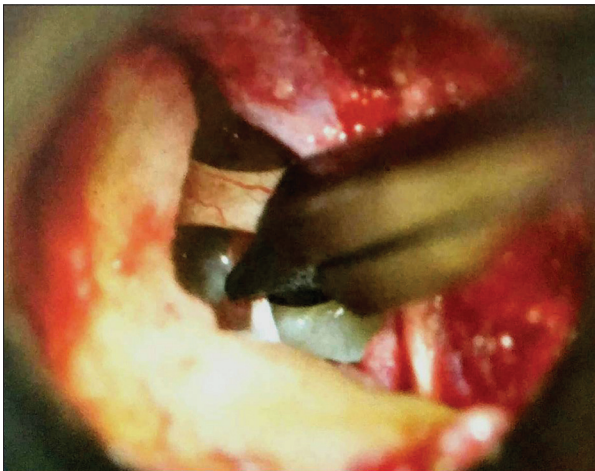


Figure 5: Exposure of the footplate of the stapes and retrotymppanic area after cutting of the stapedius muscle

three ossicles in the middle ear and thought for presence of the sesamoids in the region of the middle ear space, especially in the tendons of the stapedius and tensor tympani muscles. However, in late seventeenth century, one author tried to prove

the presence of the fourth ossicle in the stapedius tendon.^[7] However, additional ossicle was not confirmed in the stapedius muscle of the human being despite its presence in other species.^[8] The stapedius muscle is located in the tympanic cavity and connects the pyramidal eminence of the temporal bone to the posterior part of the neck of stapes.^[9] In all of the 36 cases of cadaveric temporal bone of this study, stapedius muscles were present in the middle ear cavity. The function of the stapedius muscle is to stabilize the stapes which is the smallest bone of the human being. It dampens the loud sound passing to the cochlea via the oval window and this is possible by the acoustic middle ear reflex or stapedial reflex. The stapedius muscle along with tensor tympani muscle contract in a reflex response to high intensity sounds and the stapedius muscle pull the foot plate of the stapes for reducing the amplitude of the vibrations at the oval window.^[4] This muscle also prevents the excessive movement of the stapes.^[10] The stapedial reflex plays an important role for intelligibility of the speech in noisy surrounding along with protection to the inner ear. Intact stapedial reflex decrease the undesirable upward spread towards the masking of the low frequency sounds. It does such activity by lowering the mobility of the stapes, so limiting the transmission of low frequency sounds with preservation of the transmission of the higher frequencies.^[11]

Mastoid or vertical segment of the facial nerve give a branch called nerve to stapedius muscle which innervate the stapedius muscle. The vascularity of the stapedius muscle is supplied by the stapedial branch of the posterior auricular artery, which is a branch of the external carotid artery.^[12] Contraction of the stapedius muscle causes fixation of the stapes. Contracted stapedius muscle increases the stiffening of the middle ear sound conduction mechanism. Contraction of this muscle decrease the transmission of sound by 30 decibel for frequencies <1–2 KHz.^[13] The microscopic surgical anatomy of the stapedius muscle is very important during certain otologic surgery such as stapedotomy where the surgeon cut the tendon by micro-scissor. Paralysis of the stapedius muscle leads to the hyperacusis where the patient get normal sounds as abnormally loud sound.^[14] For exposing the upper one-third of the stapedius muscle where facial nerve need not be transpositioned anterolaterally. However the facial nerve is transpositioned anterolaterally for exposing the middle one-third or belly of the stapedius muscle and lower one-third of the stapedius muscle which is found posteromedial to the vertical or mastoid segment of the facial nerve. Stapedius muscle has three parts such as upper one-third, middle one-third and lower one-third. The pyramid should be drilled with 2 mm diamond burr for exposing the upper one-third of the stapedius muscle. In this study, out of the 36 cases, 9 required removal of the bony overhanging of the posterior tympanum for complete exposure of the stapedius muscle whereas rest of the temporal bone did not need bony curettage/drilling of the scutum to expose the stapedius muscle. The distance between facial nerve and the incudostapedial joint was compared as the average length of this muscle during the stapes surgery i.e., the only visible

part of the stapedius muscle. This distance is more constant in comparison to the length of the stapedius muscle. In our study, the length of the stapedius muscle was ranging from the 8 to 11 mm with mean value was 10.60 mm and the length of the stapedius tendon was 1.5 to 2.5 mm with mean value was 2.10 mm. One study documented two cases of middle ear anatomy showing absence of the stapedius tendon.^[15] But in our study, all temporal bone showed presence of the stapedius muscle tendon. The exact anatomy of the stapedius muscle acts as an anatomical land mark during facial nerve surgery such as decompression or grafting. The knowledge of the microscopic or endoscopic anatomy of the stapedius muscle is very useful for beginners during the surgery.

The stapedius muscle and the pyramidal eminence are situated in the retro-tympanum. The pyramidal eminence and stapedius muscle have almost constant relationship to the facial nerve. However in this study, three cases showed overhanging of the tympanic segment of the facial nerve made more closure of the nerve to the stapedius muscle. In two-third of the population, the pyramidal process or eminence is lower than the insertion of the stapedius tendon to the neck of the stapes.^[9] The belly part of the stapedius muscle is a dominant portion of this muscle. One study showed stapedius tendon length 1.27 ± 0.3 mm, width: 0.45 ± 0.08 mm.^[16] One author described five types of the stapedius muscle where the typical single canal was called as the general type.^[17] In this study we could not established the different variations beside a single canal found medially to the vertical segment of the facial nerve. Variations of the stapedius muscle seem to be associated with hearing disorders.^[18]

The modern stapes surgery is relatively young discipline of Otolaryngology and it is still under continuous improvement. The site of the oval window-stapes junction was often considered as no go zone for several years. But after development of the high power microscope, Shea introduced stapedectomy for the treatment of the otosclerosis.^[19] In present day scenario, there is slight modification such as stapedotomy instead of the stapedectomy and may be performed by CO2 laser.^[20] Detail anatomy of the stapedius muscle along with its relation to facial nerve is very important for successful outcome in stapes surgery. Removal of the stapedius muscle helps to increase the exposure of the sinus tympani and sub-pyramidal space which enhances the visualization of this region along with decrease chance of the residual cholesteatoma in atticofacial disease of the middle ear cleft.

CONCLUSION

The medical students, clinicians and the otologists should have good knowledge about the microanatomy of the stapedius muscle and its relation to the facial nerve. The details of the microanatomy of the stapedius muscle are very much required

for stapes surgery and the facial nerve surgery such as facial nerve decompression and nerve grafting. The pyramidal eminence and the stapedius muscle have often constant relationship with facial nerve. Removal of the stapedius muscle helps to provide adequate exposure and visualization of the footplate and retro-tympanic area.

Financial support and sponsorship

Nil.

Conflicts of interest

There are no conflicts of interest.

REFERENCES

1. Wojciechowski T, Skadorwa T. A few points regarding recent studies on stapedius muscle anatomy. *Surg Radiol Anat* 2019;41:1099-100.
2. Williams PL, Bannister LH, Berry MM, Collins P, Dyson M, Dussek JE, et al. *Gray's Anatomy*. 38th ed., Vol. 263,284. New York: Churchill Livingstone Publisher; 1995. p. 1375-6.
3. Abdul-Baqi KJ. Objective high-frequency tinnitus of middle-ear myoclonus. *J Laryngol Otol* 2004;118:231-3.
4. Wynsberghe DV, Noback CR, Carola R. The sense. *Human Anatomy and Physiology*. 3rd ed. New York: McGraw-Hill; 1995. p. 512.
5. Rubini A, Jufas N, Marchioni D, Saxby AJ, Kong JH, Patel NP. The endoscopic relationship of the stapedius muscle to the facial nerve: Implications for retrotympanic surgery. *Otol Neurotol* 2020;41:e64-9.
6. Paaw P. *De Humani Corporis Ossibus*. Published by Justi a Colter, Lugduni Batavorum, Leiden, 1615.
7. Vesling J. *Syntagma Anatomicum*. Padova: P. Frambottos, 1651.
8. Graboyes EM, Chole RA, Hullar TE. The ossicle of Paaw. *Otol Neurotol* 2011;32:1185-8.
9. Causse JB, Vincent R, Michat M, Gherini S. Stapedius tendon reconstruction during stapedotomy: technique and results. *Ear, nose & throat journal* 1997;76(4):256-69.
10. Hough JV. Congenital malformations of the middle ear. *Arch Otolaryngol* 1963;78:335-43.
11. Borg E, Zakrisson JE. Stapedius reflex and monaural masking. *Acta Otolaryngol* 1974;78:155-61.
12. Rodriguez-Vázquez JF. Development of the stapedius muscle and pyramidal eminence in humans. *J Anat* 2009;215:292-9.
13. Elovikov AM, Selianinov AA, Lilenko SV, Nigmatullina SV. The biomechanical prerequisites for the preservation of stapedius muscle tendon during stapedoplasty. *Vestnik otorinolaringologii* 2014(5):41-4.
14. Prasad KC, Azeem Mohiyuddin SM, Anjali PK, Harshita TR, Indu Varsha G, Brindha HS. Microsurgical anatomy of stapedius muscle: Anatomy revisited, redefined with potential impact in surgeries. *Indian J Otolaryngol Head Neck Surg* 2019;71:14-8.
15. Dalmia D, Behera SK. Congenital absence of stapedius muscle tendon: Rare findings in 2 cases. *Indian J Otol* 2017;23:43-5.
16. Beger O, Koç T, Karagül Mİ, Özdemir DL, Müdüroğlu F, Cintacioiu DG, et al. Evaluation of the stapedial tendon growth dynamic in human fetuses. *Surg Radiol Anat* 2019;41:833-9.
17. Fang Y, Meyer J, Chen B. High-resolution computed tomographic features of the stapedius muscle and facial nerve in chronic otitis media. *Otol Neurotol* 2013;34:1115-20.
18. Kierner AC, Zelenka I, Lukas JR, Aigner M, Mayr R. Observations on the number, distribution and morphological peculiarities of muscle spindles in the tensor tympani and stapedius muscle of man. *Hear Res* 1999;135:71-7.
19. Shea JJ Jr. Fenestration of the oval window. *Ann Otol Rhinol Laryngol* 1958;67:932-51.
20. Cheng HC, Agrawal SK, Parnes LS. Stapedectomy versus stapedotomy. *Otolaryngol Clin North Am* 2018;51:375-92.